



University of
Salford
MANCHESTER

Migration of the Nellix Endoprosthesis

England, A, Torella, F, Fisher, R and McWilliams, R

<http://dx.doi.org/10.1016/j.jvs.2016.02.053>

Title	Migration of the Nellix Endoprosthesis
Authors	England, A, Torella, F, Fisher, R and McWilliams, R
Type	Article
URL	This version is available at: http://usir.salford.ac.uk/id/eprint/38794/
Published Date	2016

USIR is a digital collection of the research output of the University of Salford. Where copyright permits, full text material held in the repository is made freely available online and can be read, downloaded and copied for non-commercial private study or research purposes. Please check the manuscript for any further copyright restrictions.

For more information, including our policy and submission procedure, please contact the Repository Team at: usir@salford.ac.uk.

Migration of the Nellix® endoprosthesis.

Dr Andrew England¹ PhD

Dr Francesco Torella² MD, FRCS

Robert K Fisher² MD, FRCS

Professor Richard G. McWilliams³ FRCR, EBIR

Directorate of Radiography¹, University of Salford, Manchester, UK.

Liverpool Vascular & Endovascular Service (LiVES)², Royal Liverpool Hospital NHS Trust,
Liverpool, UK.

Department of Radiology³, Royal Liverpool & Broadgreen University Hospitals NHS Trust,
Liverpool, UK.

Correspondence to:- Dr Andrew England, Directorate of Radiography, Room L613, Allerton
Building, Frederick Road Campus, University of Salford, Salford, M5 4WT, UK. Tel.
+441612950703, Fax. +441612952018 (a.England@salford.ac.uk).

Abstract

PURPOSE: To report the incidence and sequelae of migration of the Nellix® endoprosthesis following endovascular aneurysm sealing (EVAS).

METHOD: A review was performed of the follow-up imaging of all EVAS patients in a University Hospital endovascular programme who had a minimum follow-up of one year. Using the first post-operative and latest follow-up CT scans, the distances between the proximal and distal borders of the stent-grafts relative to reference vessels were measured using a previously validated technique. Device migration was based on previously established criteria and defined as any stent-graft movement of ≥ 4 mm related to a predefined reference vessel. Device movement in a caudal direction was given a positive value (+) whereas movement in a cranial direction was denoted by a negative sign (-).

RESULTS: 18 patients (35 stent-grafts) were eligible for inclusion in this retrospective review. The mean (SD; range) pre-operative AAA diameter and aortic neck length were 57 (5; 50 to 67) mm and 30 (16; 6 to 62) mm, respectively. Proximal migration, according to study definitions, was identified in six stent-grafts (17%), all in a caudal direction. At one year the mean (SD; range) proximal migration distance was +6.6 (1.6; +4.7 to +9.2) mm. Migration occurred in a single stent-graft in four patients and bilaterally in one. Distally, there were no cases of migration.

CONCLUSIONS: Proximal migration of the Nellix® endoprosthesis does occur and in our series was without any sequelae. Further investigations into the long-term positional stability of the Nellix® device are required together with a more thorough understanding of the aetiology and consequences of migration.

Introduction

The Nellix® endoprosthesis (Endologix Inc, Irvine, California, USA) has been used to treat numerous patients with abdominal aortic aneurysms (AAA) [1-3]. The use of a sac-anchoring endograft such as the Nellix® has brought a change in the approach to aneurysm exclusion.

The Nellix® device consists of balloon expandable stents surrounded by endobags that are filled with a polymer thereby sealing the aneurysm. This change in approach to AAA therapy has been termed endovascular aneurysm sealing or EVAS. By sealing the aneurysm sac instead of excluding it with only proximal and distal fixation, the risk of stent migration and endoleaks has been reported to have theoretically diminished [4, 5].

Complications have, however, been reported following implantation of the Nellix® device. Böckler and colleagues, in a recent multicentre case series analysis, reported type 1a, type 1b and type II endoleaks in a small number of patients [3]. Authors in the same publication documented the need for aneurysm-related interventions in 15 patients (9%) but there was an absence of any aneurysm ruptures or open surgical conversions.

This report aims to investigate early migration of the Nellix® endoprosthesis in patients with a minimum follow-up of 12 months.

Methods

Study Design and Technique

EVAS was introduced into our practice in December 2013. Suitability for EVAS was determined by a team of clinicians using arterial phase computed tomography (CT) and confirmed at a weekly multidisciplinary team review of all prospective elective patients for AAA

repair. The technique of EVAS has been described extensively within the literature [1, 6, 7]. This project fell within a programme of studies evaluating EVAS at our institution and as such formal ethics committee approval was not required. Patient informed consent was obtained for the EVAS procedure and this included an understanding that procedural outcomes would be evaluated and reported accordingly.

Follow-up Imaging Protocol

Our follow-up protocol includes post-operative imaging by conventional abdominal radiography on day 1, duplex ultrasound and arterial phase CT at 1 month, followed by yearly abdominal radiographs, duplex scans, and arterial phase CT except in patients with significant renal impairment. All CT acquisitions conformed to a standard follow-up protocol and CT data were reconstructed using the thinnest available slice (≤ 2 mm) prior to review.

Study Measurements

For inclusion, all patients were required to have had a baseline (first) post-operative CT scan (within six weeks following device implantation) and at least one additional CT scan (minimum of 12 months from the initial implantation procedure) available in DICOM (Digital Imaging and Communication in Medicine) format.

Our methods for assessing and defining stent-graft migration are based on previous experimental work [8] and have been used to report migration in two clinical studies [9, 10]. Previous experimental work included an assessment of the bias (difference between true migration and the CT assessment) and both intra- and inter-observer variability [8]. Migration was defined as cranial or caudal movement of the stent-graft, relative to a vascular landmark of ≥ 4 mm.

In order to quantify stent-graft migration a central luminal line (CLL) was created from CT data on a computer workstation (Carestream Health Inc, Rochester, NY, USA). Confirmation that the CLL ran through the central luminal channel of the aorta and common iliac arteries (CIA) was obtained by visual inspection of the reconstructed images. For proximal migration the native vascular reference point was the superior mesenteric artery (SMA). The distance between the inferior border of the SMA and the first appearance of both the left and right stent-grafts was measured separately (**Fig 1**). At the distal margins the common iliac artery bifurcation was used as the reference point (**Fig 2**). Curved length measurements allowed the measurement from the proximal stent-grafts to the SMA and from the distal stent-grafts to the common iliac artery bifurcation on the 1st post-operative CT scan. Each CLL measurement was then compared with the same measurement on the one year CT scan. Measurement differences between the 1-month and 1-year CT scan, for the same anatomical location, were used to determine if there was device migration. Caudal migration was indicated by a positive value and cranial with a negative value. Measurements were recorded electronically to 1/10 of a millimetre.

Based on the CLL measurements any patient meeting our definition of migration was subjected to further scrutiny (**Fig 3**). This included visual analysis of the reconstructed aortic segment from which specific landmarks were identified within the aortic wall such as calcification. These images, in addition to the CLL data, were assessed by two observers (authors) in order to confirm whether the device had migrated. In addition to migration assessment the study group was subject to further evaluations which included review of follow-up imaging records and clinical notes. With respect to this study, the aortic neck was defined as the distance from the lower margin of the most caudal renal artery to a point distally where the

lumen diameter increases by a maximum of 20 %, after which point it was considered to be the start of the aneurysm.

Statistical Analysis

SPSS 20.0 (IBM Corp, Armonk, New York) was used for the statistical analysis. Variables were summarised as mean (standard deviation; range) in the cases of distributions that were approximately normal. The median (inter-quartile range; range) were reported if the data were not approximately normally distributed. Categorical data were summarised as frequencies together with their respective percentages.

Results

18 patients were treated by EVAS at our institution between December 2013 and August 2014 and were eligible for inclusion in this retrospective review. Additional patients had undergone EVAS but either their follow-up was not past one year or that they did not have two follow-up CT scans available. For included patients the mean (SD; range) age was 80 (7; 69 to 91) years, 10 (56%) were men and the mean (SD; range) maximum preoperative AAA diameter was 58 (5; 50 to 67) mm. Of the 18 patients the mean (SD; range) neck length was 30 (16; 6 to 62) mm. Two Nellix® devices were deployed in two patients with aortic necks less than 10 mm in length. Based on the Manufacturer's *Instructions for Use* (IFU)[11] these cases were 'off-label' but there were other areas within the infrarenal aorta which were deemed suitable for sealing. 17

(94%) patients had EVAS using paired stent-grafts deployed into both the left and right common iliac arteries, a single patient had a single 'off-label' aorto-uniiliac (AUI) device implanted.

Mean (SD; range) follow-up was 13.5 (0.8; 12.3 to 15.1) months. Maximum aneurysm diameter remained relatively stable during follow-up, the mean (SD; range) change was 1.1 (2.8; -3.0 to 7.0) mm.

Device migration

Based on the analysis of 36 follow-up CT scans the assessment of proximal and distal migration was possible in all patients. A total of 35 stent-grafts were assessed for proximal migration (one AUI), 6 stent-grafts (17%) were determined to have migrated mean (SD; range) +6.6 (1.6; +4.7 to +9.2) mm with respect to their initial implanted position. Proximal migration was present in a single stent-graft in four patients and a further patient exhibited proximal migration in both stent-grafts (**Table I**). One of the single stent-graft migrations was in a patient with an off-label AUI device and migration of both stent-grafts occurred in a patient with a 6 mm aortic neck. Distally, there were no cases of stent-graft migration identified according to study definitions.

Discussion

We have identified five patients who on post-EVAS surveillance imaging demonstrated CT evidence of proximal device migration (≥ 4 mm). All device migrations occurred at the proximal margins and movements ranged from 4.7 to 9.2 mm in a caudal direction. Based on our cohort of 18 patients this equates to a 28% migration rate. To our knowledge, this is the first report of migration of Nellix® devices. This may be explained by the novelty of EVAS and the very small number of cases reported in the literature, almost invariably with short follow-up periods. Furthermore, expert commentary within the literature suggests that attachment site fixation

issues are unlikely to be a complication following EVAS [4,5] and, therefore, may not be proactively scrutinised during follow-up. It is important to note that there are several definitions of device migration within the literature (11, 12). The most widely used is from the Society for Vascular Surgery/International Society for Cardiovascular Surgery but this over 15 years old and was developed in an era of standard infra-renal EVAR and single detector row CT technology. Within these standards a larger migration definition (≥ 10 mm) is recommended and if applied to this study it would have generated a zero rate of migration. With the increasing complexity of endovascular aortic procedures and newer technologies e.g. EVAS attracting widespread clinical use we would argue for a more conservative definition. Our definition chosen for this study had a separate validation and reliability study published (8) and has also been used to report migration in two recent clinical publications (9, 10).

The Nellix® device does not have active fixation but device stability is achieved through support from the stent/endobag complex occupying all of the available space. Narrowing in the infra-renal neck and the aortic bifurcation supports the cured polymer within the endobags and resists migration. However, long-term stability requires that the aorta and the iliac arteries do not dilate, above or below the endobags and that the volume and shape of the unpressurised aneurysm and thrombus do not change. If either situation occurs, then this may provide one possible explanation as to why there are cases of proximal migration following EVAS. The Nellix® device experiences distraction forces similar to a standard EVAR device (13), but does not have the fixation through barb engagement or the radial force associated with self-expanding stents. These distraction forces may also work laterally and drive the endobag through the sac thrombus, thereby facilitating migration. Such bowing of the stent and endobag may be associated with a change in appearance of the Nellix® within a sac of equal volume or equal

thrombus volume. This will be studied as part of future research. If the endobags migrate then the relationship between them and the aortic wall established at deployment is lost. This may result in a flow channel developing alongside the endobag within the aortic neck with a subsequent endoleak occurring. Although this was not seen in our series, those patients in whom there has been migration identified require close observation. The series reported reflects migration of the stents and not the endobags within the aorta. Visualisation of the chromium-cobalt stents is very clear and, therefore, allows accurate scrutiny. The endobags, however, are not as clearly defined and it is less reliable to assess their movement. Bench observations have suggested that some independent movement of the stent in relation to the endobag is possible. The precise extent of this is not clear and would need further investigation. Migration of the stent of greater than 4 mm as reported in over a quarter of this series is very likely to represent some migration of the endobag also, albeit without loss of seal in the short-term. It is not clear whether these initial movements of the Nellix® are a period of stabilisation or whether movements are likely to be progressive.

Caudal migration within the proximal sealing zone after EVAS is of concern. The manufacturers IFU (14) states that the neck should be at least 10 mm in length with variation in diameter no more than 20%. Applying these criteria strictly rendered some of our patients outside of the IFU, whilst there was a secondary neck within which sealing could be anticipated. This is evidenced by the fact that in patient 17 the neck was deemed 6 mm in length and yet, despite a 9 mm caudal migration, there was no endoleak. This was due to a conical secondary neck that did not fulfil IFU criteria but did facilitate sealing. It is generally accepted that adherence to IFU reduces complications but the authors recognise that there are variations in aortic morphology tolerated for sealing. Further studies, with a larger sample size and a

multicentre focus, are required in order to fully understand how the aneurysm morphology may influence migration and its possible consequences.

Within our cohort no cases of migration have been associated with any adverse event. It is also not clear why some patients experience stent-graft movement and some do not. Small movements of the Nellix® system could result from aneurysm morphology changes during follow-up and the long-term significance is currently unknown. Movements at the proximal landing zones do raise questions regarding the need for long-term follow-up in EVAS patients. Careful follow-up of EVAS patients is paramount in order to identify whether movements represent a benign settling period or whether these movements could transform into more serious complications. Follow-up intervals and imaging methods are often debated when deploying aortic devices. Within our practice follow-up imaging was based on the combined use of duplex ultrasound, CT and abdominal radiography. Reducing the number of CT scans has accepted benefits including reductions in cost, radiation dose and the risk of contrast induced nephropathy. Review of migration cases within our series has provided some evidence that EVAS related migration can be identified using abdominal radiography (Fig 4).

There were no cases of distal (iliac) migration within our cohort. A number of factors could explain this including the forces acting on the distal landing zones, length of follow-up, level of stent-graft engagement within the common iliac artery and the overall extent of disease. Forces acting at the proximal landing zones are greater than those in at the distal landing and are in an opposite direction [15]. The length of coverage of the common iliac artery is a potential factor in preventing distal stent-graft migration into the aneurysm sac [16]. Iliac artery coverage and angulation was not assessed in this study but could have a role in preventing migration.

Conclusion

Endovascular sealing is a promising technique for treating AAAs. Early efficacy data are encouraging, however, the safety of this technique remains under scrutiny. Proximal migration of the Nellix® endoprosthesis does occur but it is not clear whether this will translate into associated complications. Further investigations into the long-term positional stability of the Nellix® device are required together with a more thorough understanding of the aetiology of any migration.

References

1. Donayre CE, Zarins CK, Krievins DK, Holden A, Hill A, Calderas C, et al. Initial clinical experience with a sac-anchoring endoprosthesis for aortic aneurysm repair. *J Vasc Surg* 2011;53:574-82.
2. Krievins DK, Holden A, Savlovskis J, Calderas C, Donayre CE, Moll FL, et al. EVAR using the Nellix sac-anchoring endoprosthesis: treatment of favourable and adverse anatomy. *Eur J Vasc Endovasc Surg*;201142:38-46.
3. Böckler D, Holden A, Thompson M, Hayes P, Krievins D, de Vries JP, et al. Multicenter Nellix EndoVascular Aneurysm Sealing system experience in aneurysm sac sealing. *J Vasc Surg*. 2015;62:290-8.

4. van den Ham LH, Zeebregts CJ, de Vries JP, Reijnen MM. Abdominal Aortic Aneurysm Repair Using Nellix Endovascular Aneurysm Sealing. *Surg Technol Int* 2015;26:226-31.
5. Holden A. Endovascular sac sealing concept: will the Endologix Nellix device solve the deficiencies. *J Cardiovasc Surg (Torino)* 2015;56:339-53.
6. Böckler D, Peters AS, Pfeiffer S, Kovacs B, Geisbusch P, Bischoff MS, et al. Nellix endovascular aneurysm sealing (EVAS)—a new technology for endovascular management of infrarenal aortic aneurysms. *Zentralbl Chir.* 2014;139:562–568.
7. McWilliams RG, Fisher RK, England A, Torella F. Observations on surveillance imaging after endovascular sealing of abdominal aortic aneurysms with the Nellix system. *J Endovasc Ther* 2015;22:303-6.
8. England A, García-Fiñana M, How TV, Vallabhaneni SR, McWilliams RG. The accuracy of computed tomography central luminal line measurements in quantifying stent graft migration. *J Vasc Surg* 2012;55:895-905.
9. England A, García-Fiñana M, Fisher RK, Naik JB, Vallabhaneni SR, Brennan JA, McWilliams RG. Migration of fenestrated aortic stent grafts. *J Vasc Surg* 2013;57:1543-52.
10. England A, García-Fiñana M, McWilliams RG; Collaborators. Multicenter retrospective investigation into migration of fenestrated aortic stent grafts. *J Vasc Surg* 2015;62:884-92.
11. Cao P, Verzini F, Zannetti S, De Rando P, Parlani G, Lupattelli L, et al. Device migration after endoluminal abdominal aortic aneurysm repair: analysis of 113 cases with a minimum follow-up period of 2 years. *J Vasc Surg* 2002;35:229-35.

12. Chaikof EL, Blankensteijn JD, Harris PL, White GH, Zarins CK, Bernhard VM, et al. Reporting standards for endovascular aortic aneurysm repair. *J Vasc Surg* 2002;35:1048-60.
13. Swaelens C, Poole R, Torella F, McWilliams RG, England A, Fisher RK. Type IIIb endoleak and relining: a mathematical model on distraction forces. *J Endovasc Ther* (in press)
14. Endologix. Nellix Endovascular Aneurysm Sealing System, Instructions for Use. 2015, C012760-1 Rev. E.
15. Mohan IV, Harris PL, Van Marrewijk CJ., Laheij RJ, How TV. Factors and forces influencing stent-graft migration after endovascular aortic aneurysm repair. *J Endovasc Ther* 2002;9:748-55.
16. Alerci M, Wyttenbach R, Bogen M, Von Segesser LK, Gallino A, Inglese L. Endovascular treatment of proximal bilateral iliac limb dislocation and kinking following endovascular abdominal aortic aneurysm. *Cardiovasc Intervent Radiol* 2005;28:521-5.

Legends for Figures

Figure 1. CT central luminal line measurements illustrating the assessment of proximal migration. In this case (9) the left proximal stent-graft was 15.6 mm inferior to the superior mesenteric artery (SMA) on the 1-month post-EVAR CT. At 1-year the left proximal stent-graft had migrated caudally by 7.1 mm and is resting 22.7 mm inferior to the SMA.

Figure 2. CT central luminal line measurements illustrating the assessment of distal migration. In this case (3) the left distal stent-graft was 20.2 mm superior to the common iliac artery bifurcation on the 1-month CT scan. By 1-year, the left distal stent-graft was located 19.2 mm superior to the CIA bifurcation, with no evidence of migration.

Figure 3. Coronal maximum intensity projections (MIP) demonstrating the migration of both stent-grafts (case 17) from the 1-month post-EVAS CT scan to the 1-year post-EVAS CT scan. Coronal MIP images were used as part of further scrutiny in order to visually verify (within the research team) the existence of migration.

Figure 4. Lateral abdominal X-ray images at 1-month and 12-months illustrating the radiographic appearances of Nellix® migration.

Figure 1

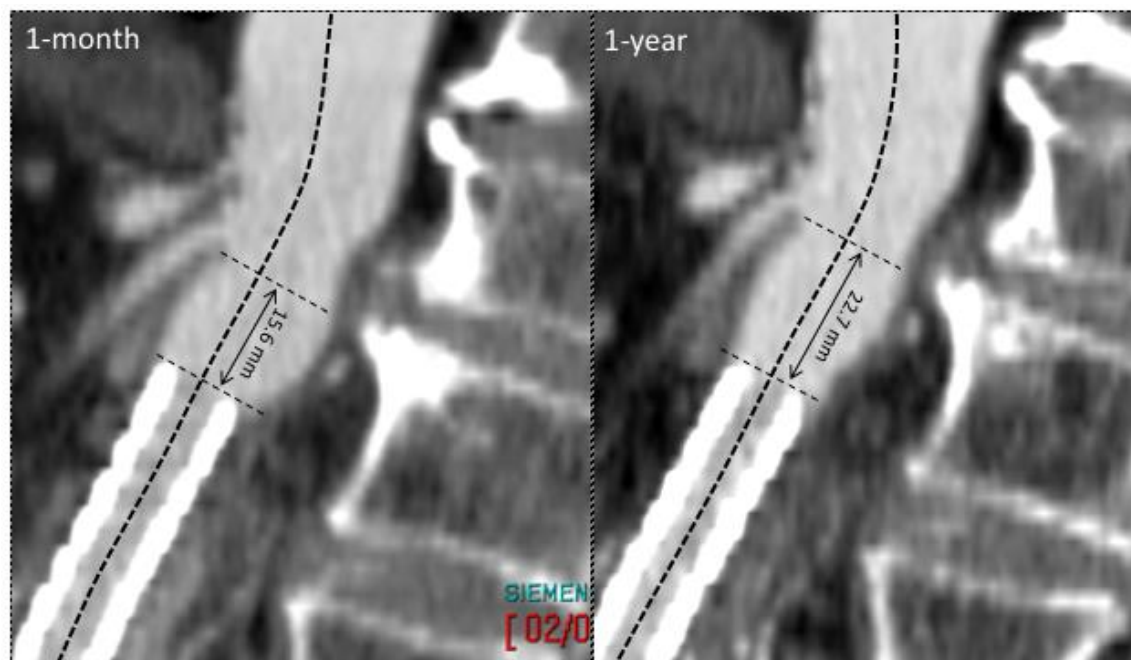


Figure 2

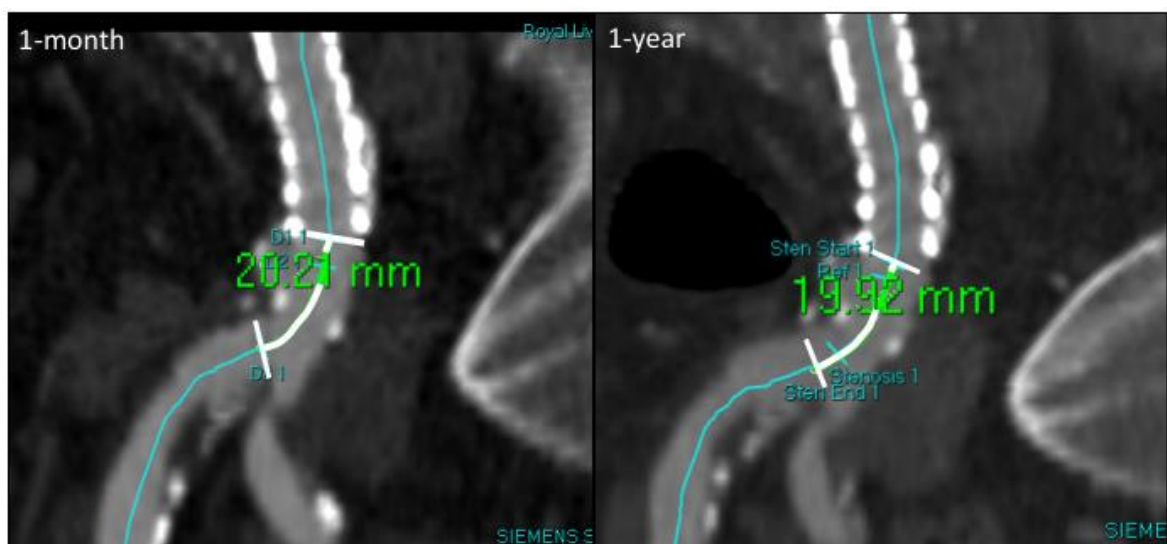


Figure 3

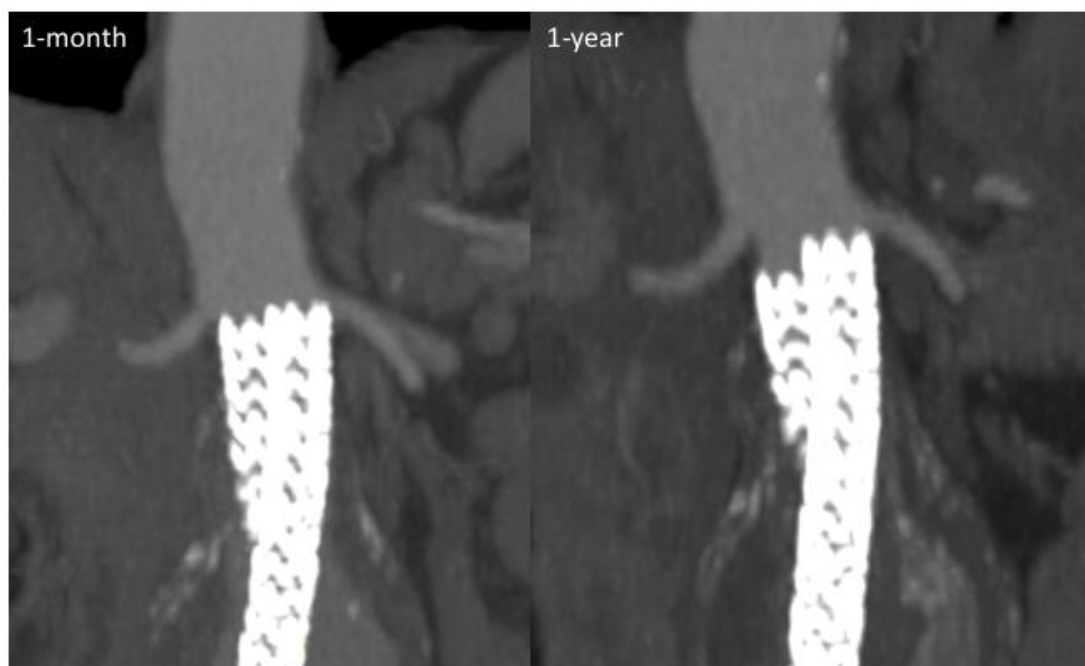

Figure 4

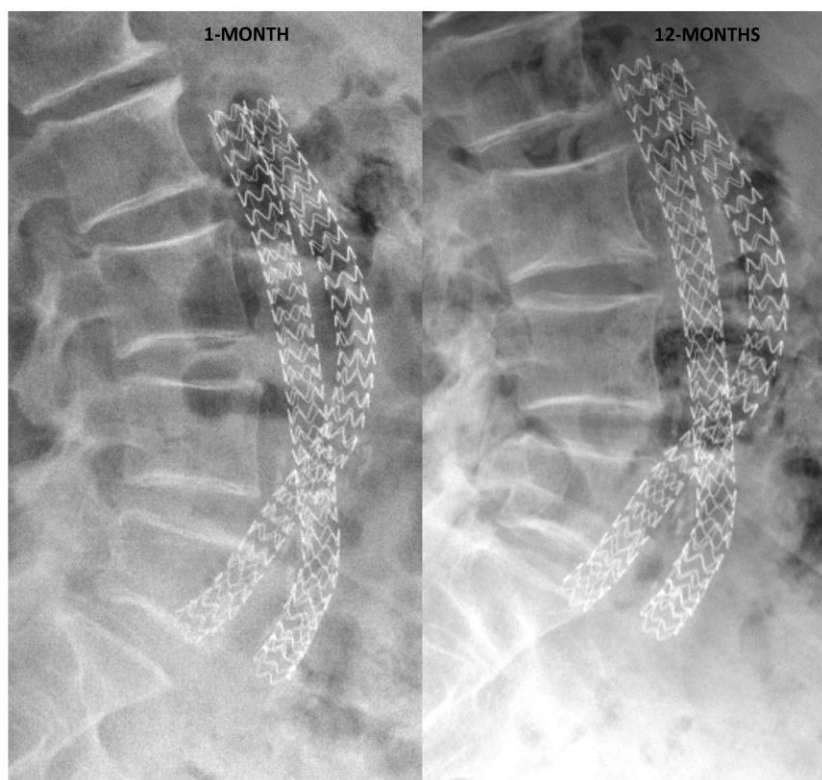


Table I. Details surrounding the six cases (five patients) of proximal stent-graft migration.

Patient		Migration		Pre-operative morphology					Intra-operative		Follow-up			
Case number	Gender / Age (years)	Location	Distance (mm)	Neck Diameter (mm)	Neck Length (mm)	Neck Angulation (°)	Max. AAA Diameter (mm)	Lumen / Thrombus volume (ml)	Endosealant volume (ml)	Complications	AAA Diameter Change, mm (%)	Complications		Total (months)
												Early	Late	
4	M (90)	Proximal (Left)	+4.7	31	62	43	58	90 / 54	75	No	6 (10)	No	No	13.2
9	F (78)	Proximal (Right)	+7.1	22	16	31	56	50 / 79	50	No	-3 (5)	No	No	13.5
12	M (71)	Proximal (Right)	+6.4	30	15	32	67	55 / 106	58	No	-1 (2)	No	No	13.0
13*	F (83)	Proximal (Left)	+5.2	20	54	29	50	28 / 38	31	Ruptured EIA	0 (0)	Paraparesis, NSTEMI, femoral fracture	EIA stenosis	12.6
17	F (87)	Proximal (Left)	+9.2	30	6	17	67	102 / 238	88	No	5 (7)	No	No	13.6
		Proximal (Right)	+6.7											

*aorto uni-iliac configuration; EIA, external iliac artery; M, male; F, female; mo, months; NSTEMI, non ST elevated myocardial infarction. Max, maximum.